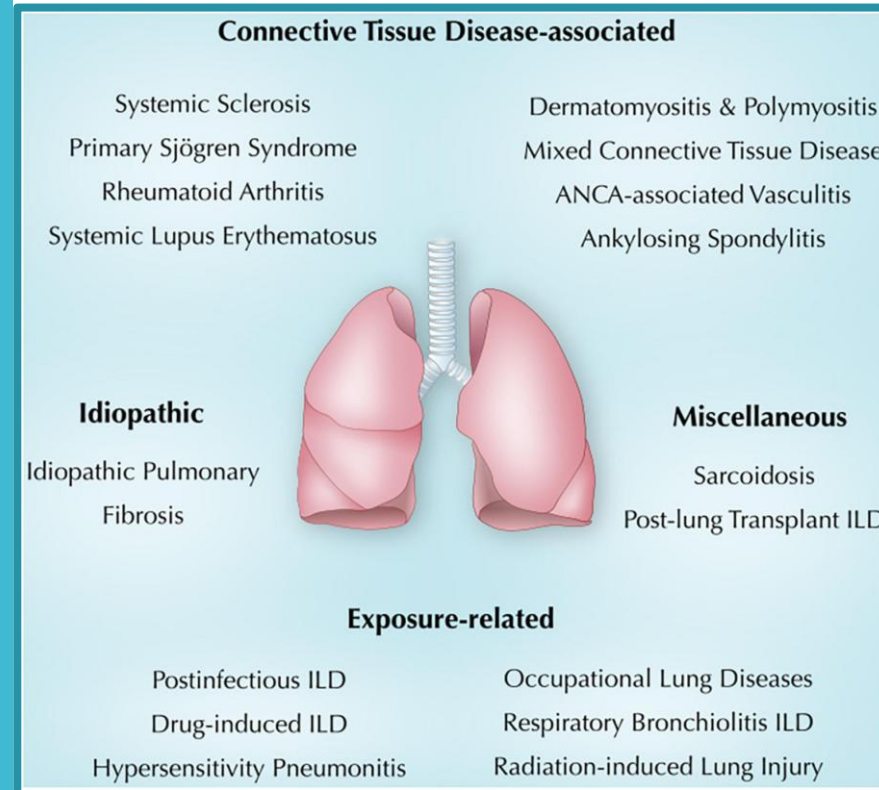




# ULOGA PULMOLOGA U REUMATOLOŠKOM TIMU

Ana Brajdić Šćulac, dr.med.  
spec.pulmologije

# IZVANZGLOBNE MANIFESTACIJE REUMATSKIH BOLESTI

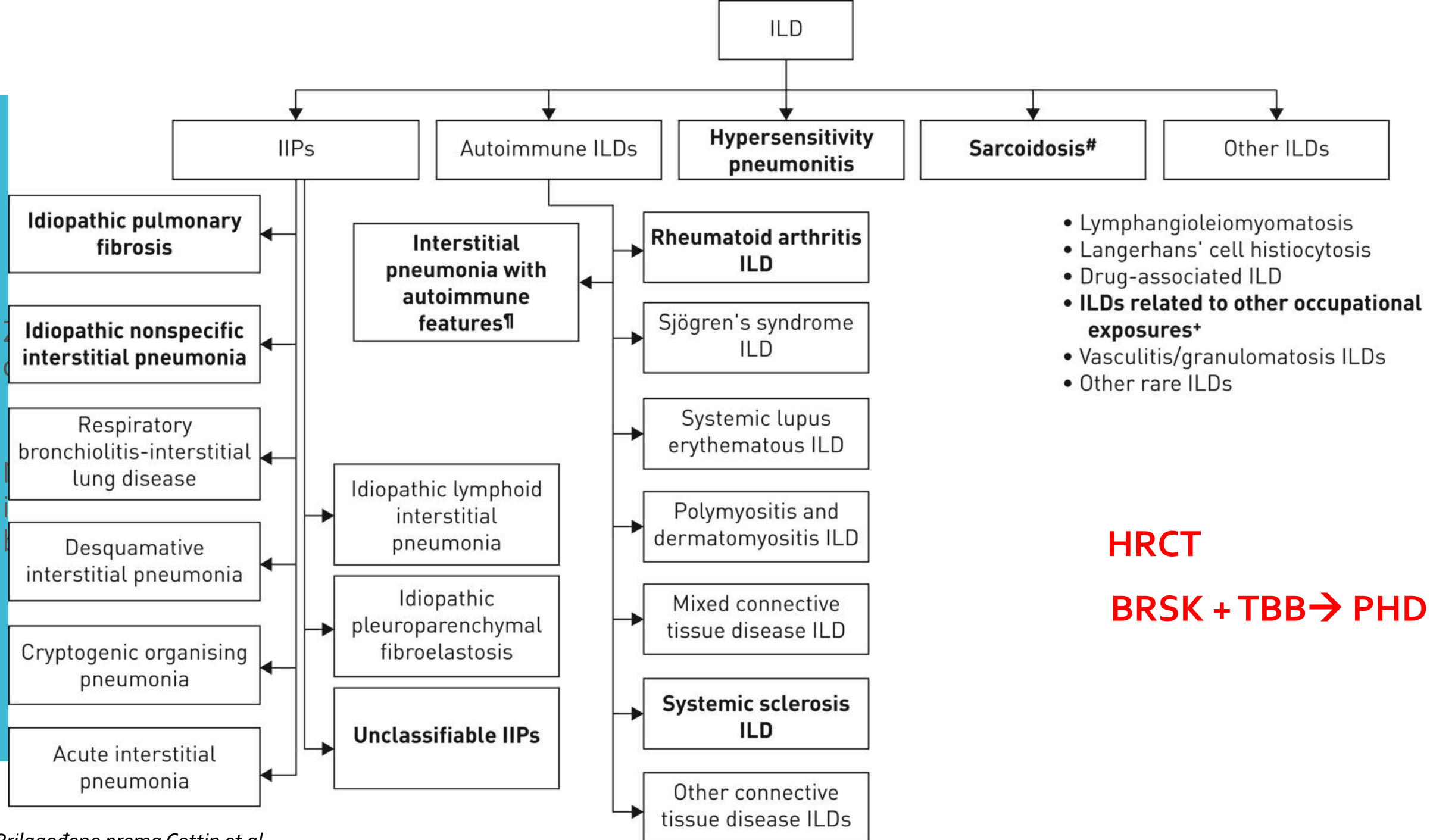


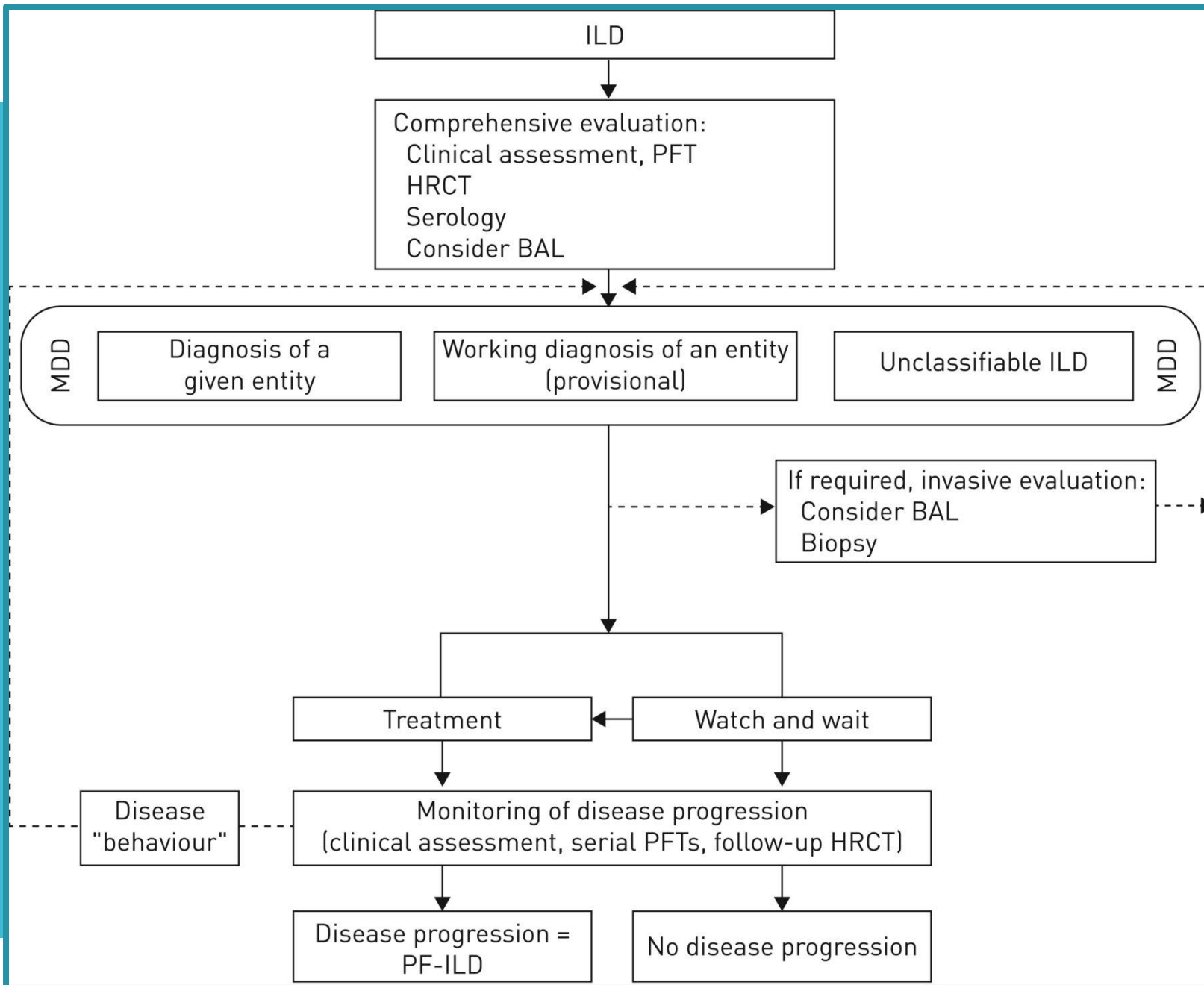
Prilagođeno prema Sweis G et al.

skim bolestima → zahvaćenost  
pluća i srce (*Hoffman T et al*)

ki i klinički izazov

ve liječenja?





*prilagođeno prema Cottin V et al*

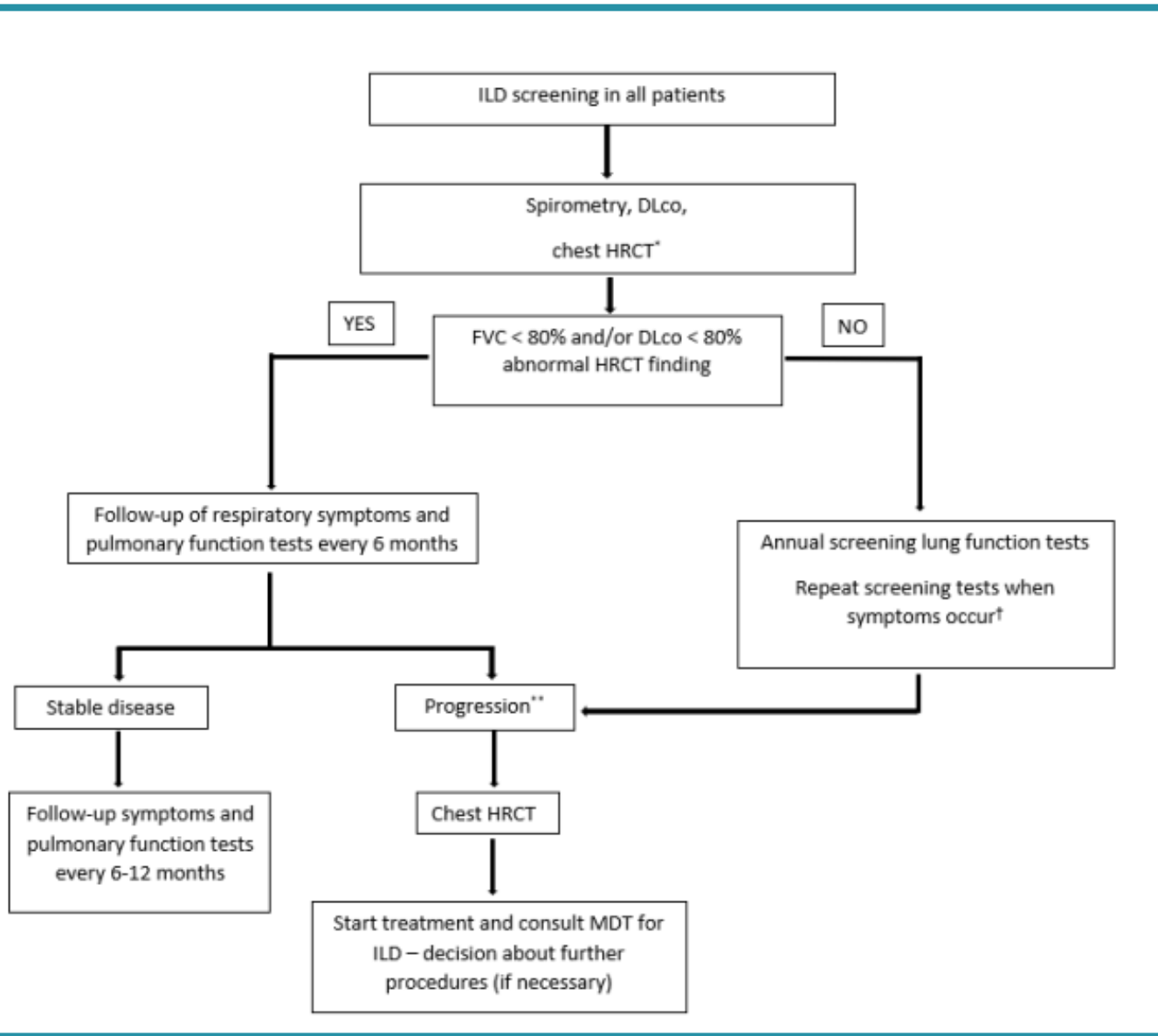


- Postavljanje sumnje
- Pravovremena dijagnoza
- Precizno praćenje

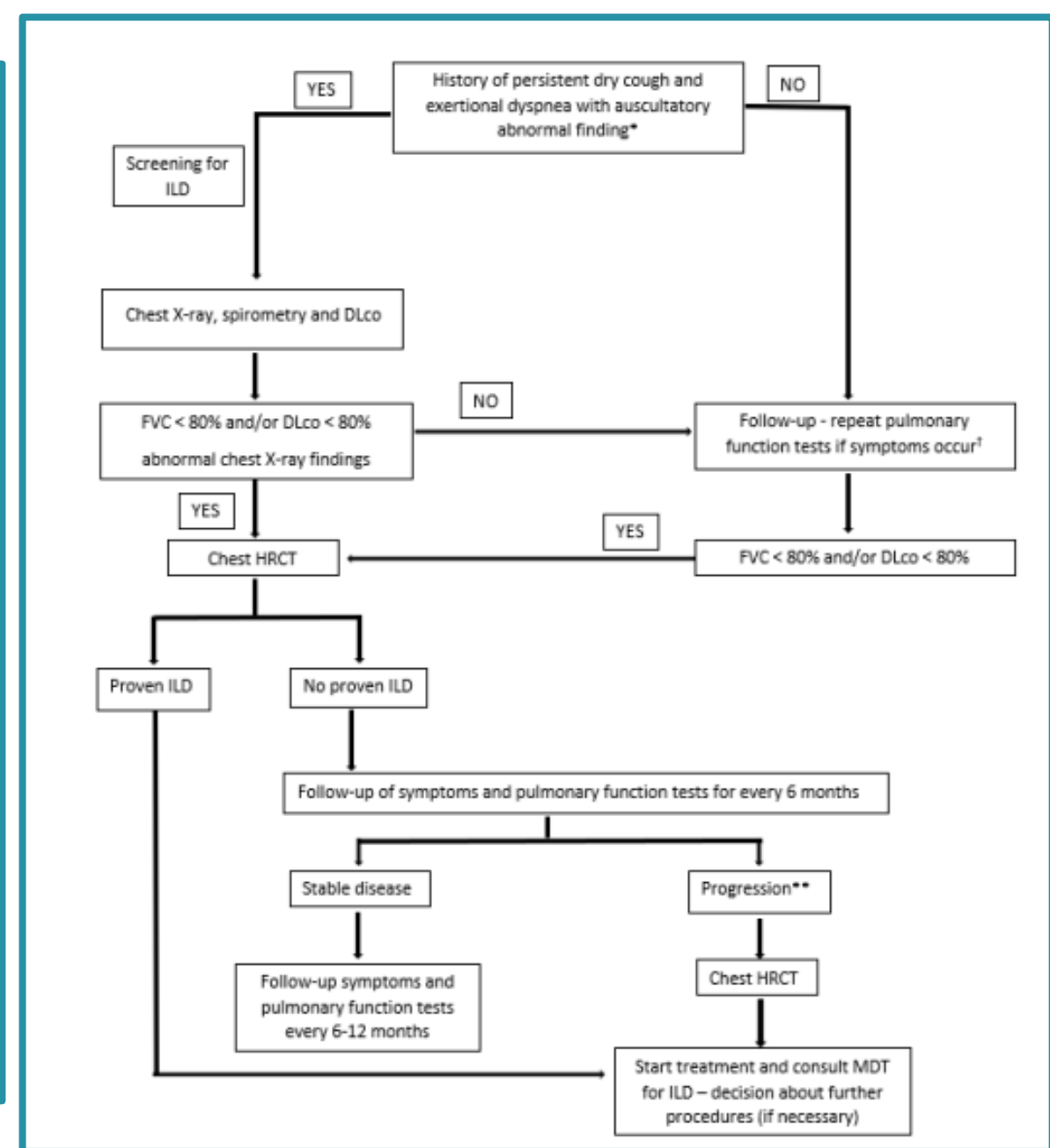
Article

## Delphi-Based Consensus on Interstitial Lung Disease Screening in Patients with Connective Tissue Diseases (Croatian National-Based Study)

Mislav Radić <sup>1,2,\*</sup>, Srđan Novak <sup>3,4</sup>, Marko Barešić <sup>5,6</sup>, Ana Hećimović <sup>6,7</sup>, Dijana Perković <sup>1,2</sup>, Jasna Tekavec-Trkanjec <sup>8</sup>, Miroslav Mayer <sup>5,6</sup>, Višnja Prus <sup>9,10</sup>, Jadranka Morović-Vergles <sup>6,11</sup>, Daniela Marasović Krstulović <sup>1,2</sup>, Mislav Cerovec <sup>12</sup>, Ljiljana Bulat Kardum <sup>3,13</sup>, Miroslav Samaržija <sup>6,7</sup> and Branimir Anić <sup>5,6</sup>



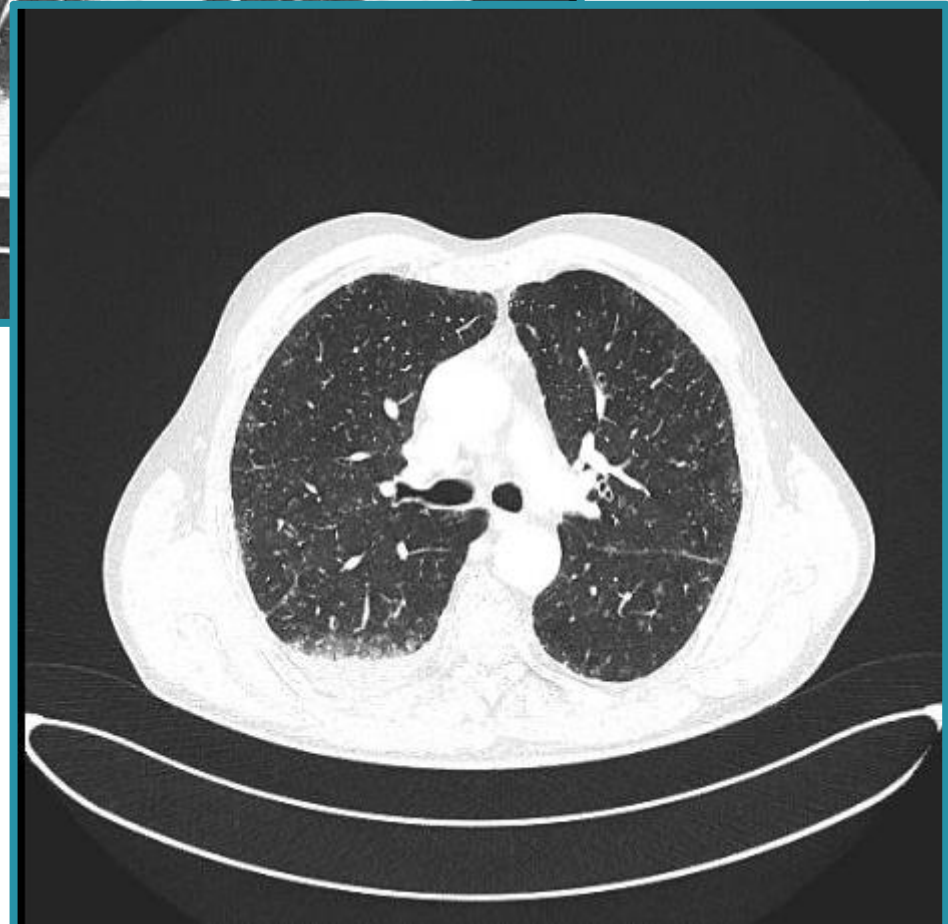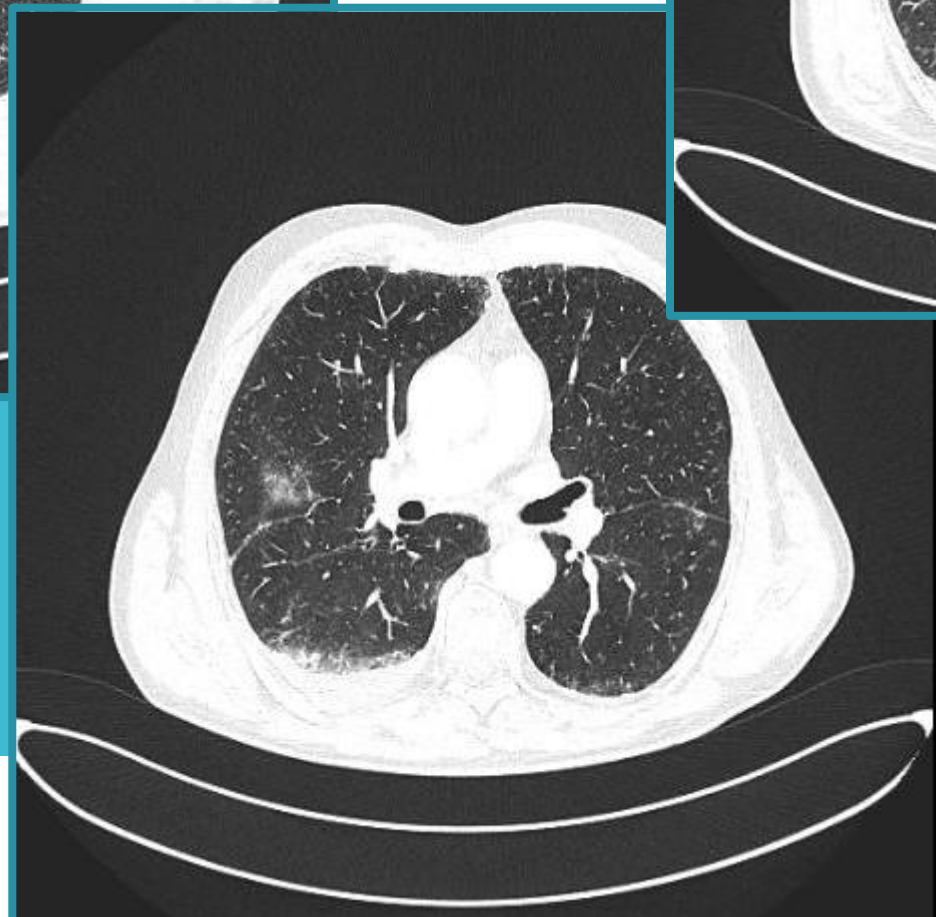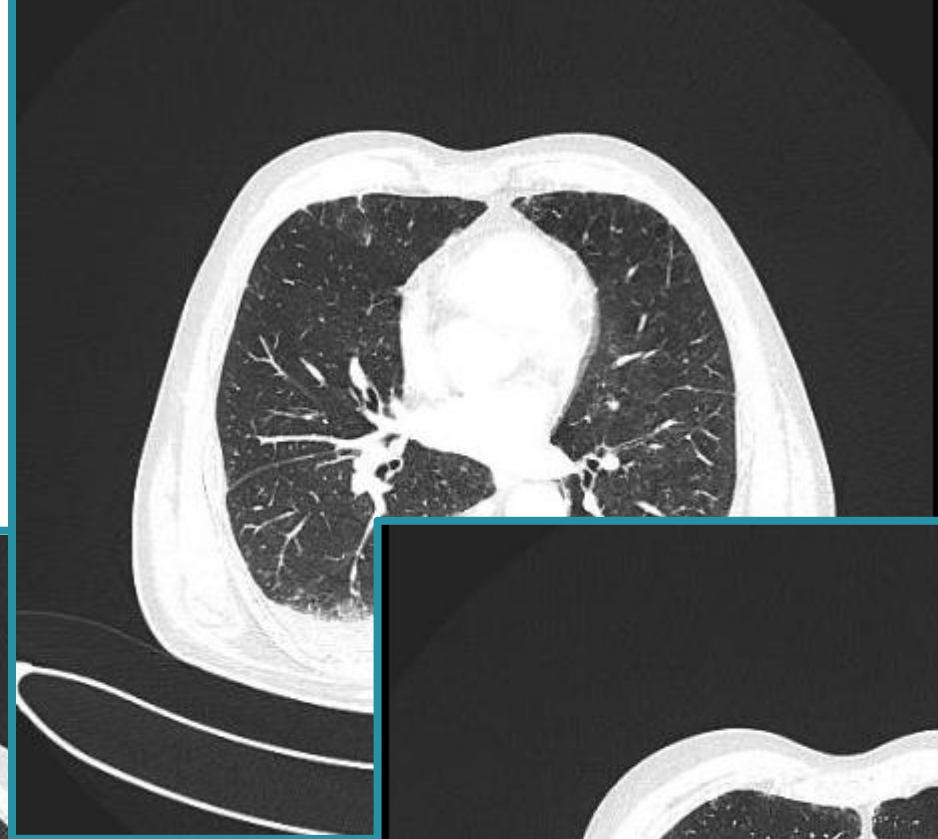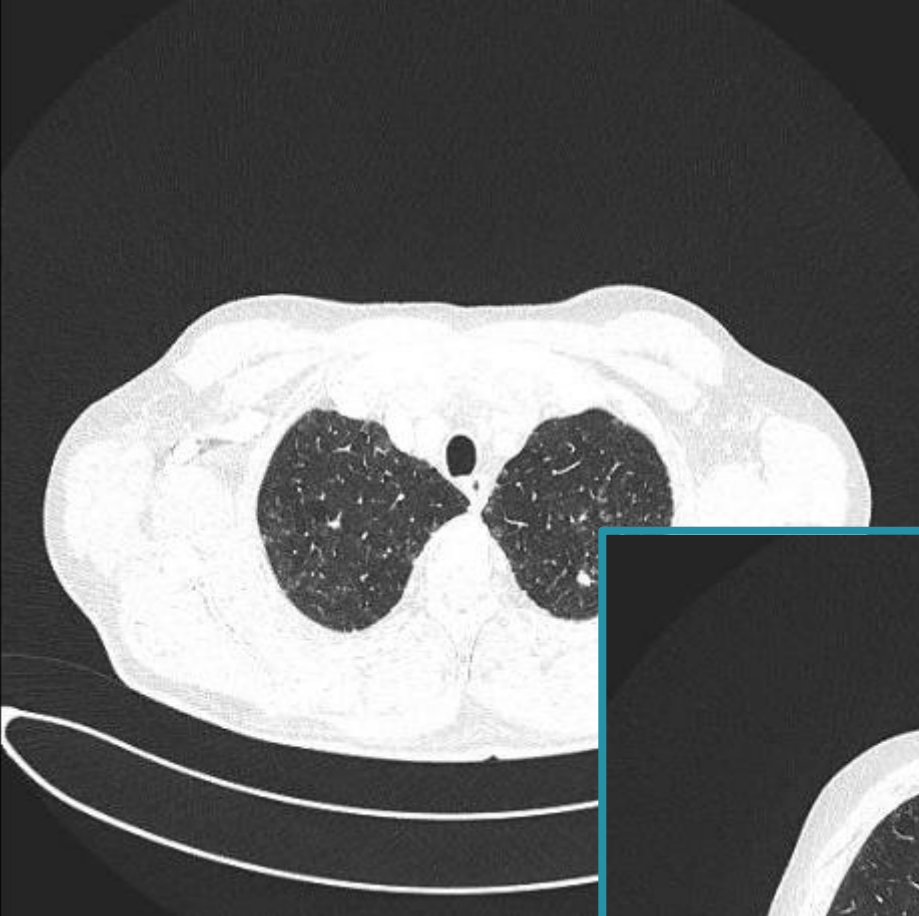
Screening za ILD u bolensika sa novootkrivenim RA, pSS ili SLE  
Prilagođeno prema Radić M et al



Screening za ILD u bolensika sa novootkrivenim MCTD, IIM, SSC  
Prilagođeno prema Radić M et al

# PRIKAZ SLUČAJA

- Bolesnik star 64 godine, od 2010. u praćenju reumatologa
- Dg. RA
- 2011.godine uvedena biološka terapija etanerceptom
- Klinički uglavnom dobro do lipnja 2023 → ebetrexat zamijenjen leflunomidom zbog GIT tegoba
- Pogoršanje bolesti
- Otekline koljena, skočnog zgloba, probadajuća bol u densom hemitoraksu
- Febrilitet uz noćno znojenje
- Gubitak na težini
- Pleuritična bol i nadražajni kašalj





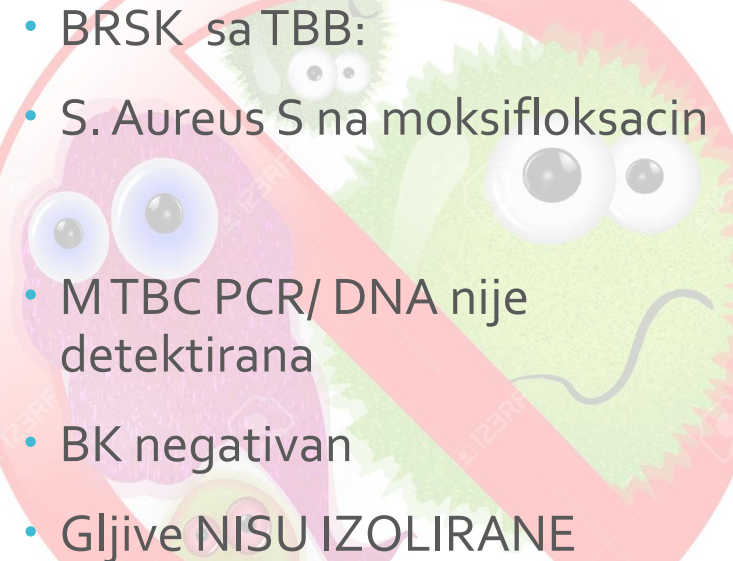
UZV PLEURE/ minimalni pl  
izljev nedostupan punkciji

Specifična upala?

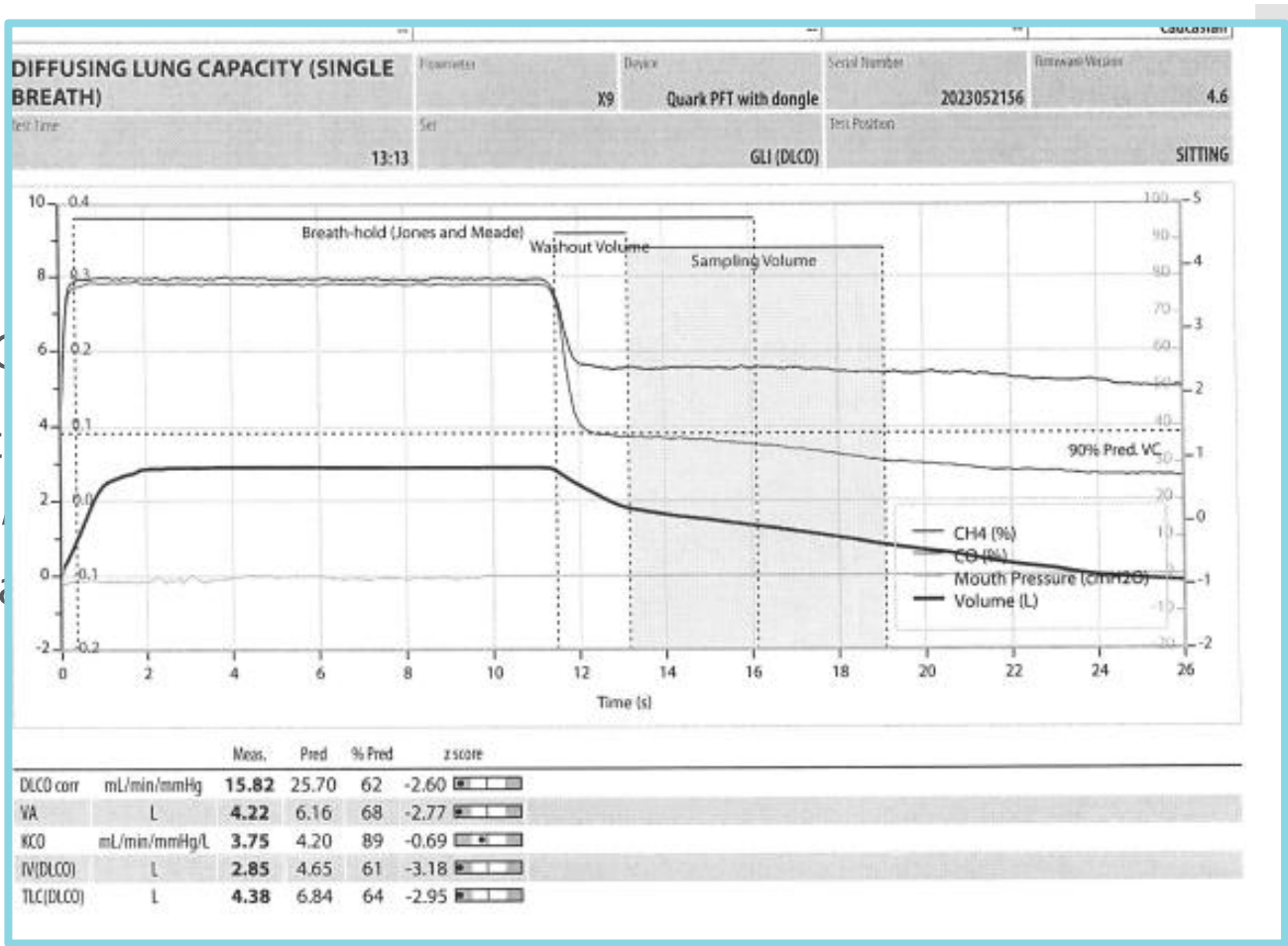
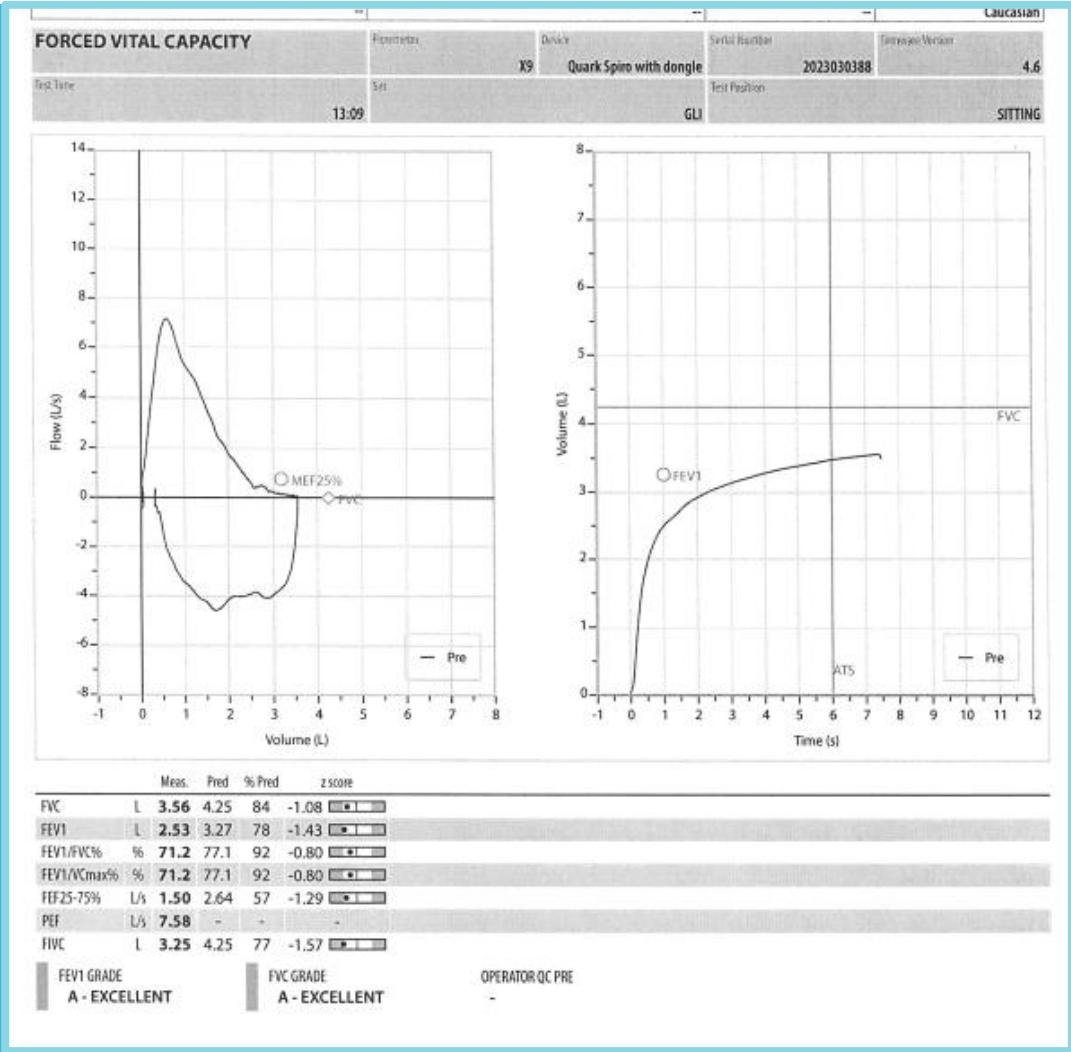
ILD?

Empirijski uveden  
respiratorni kinolon nakon  
BRSK

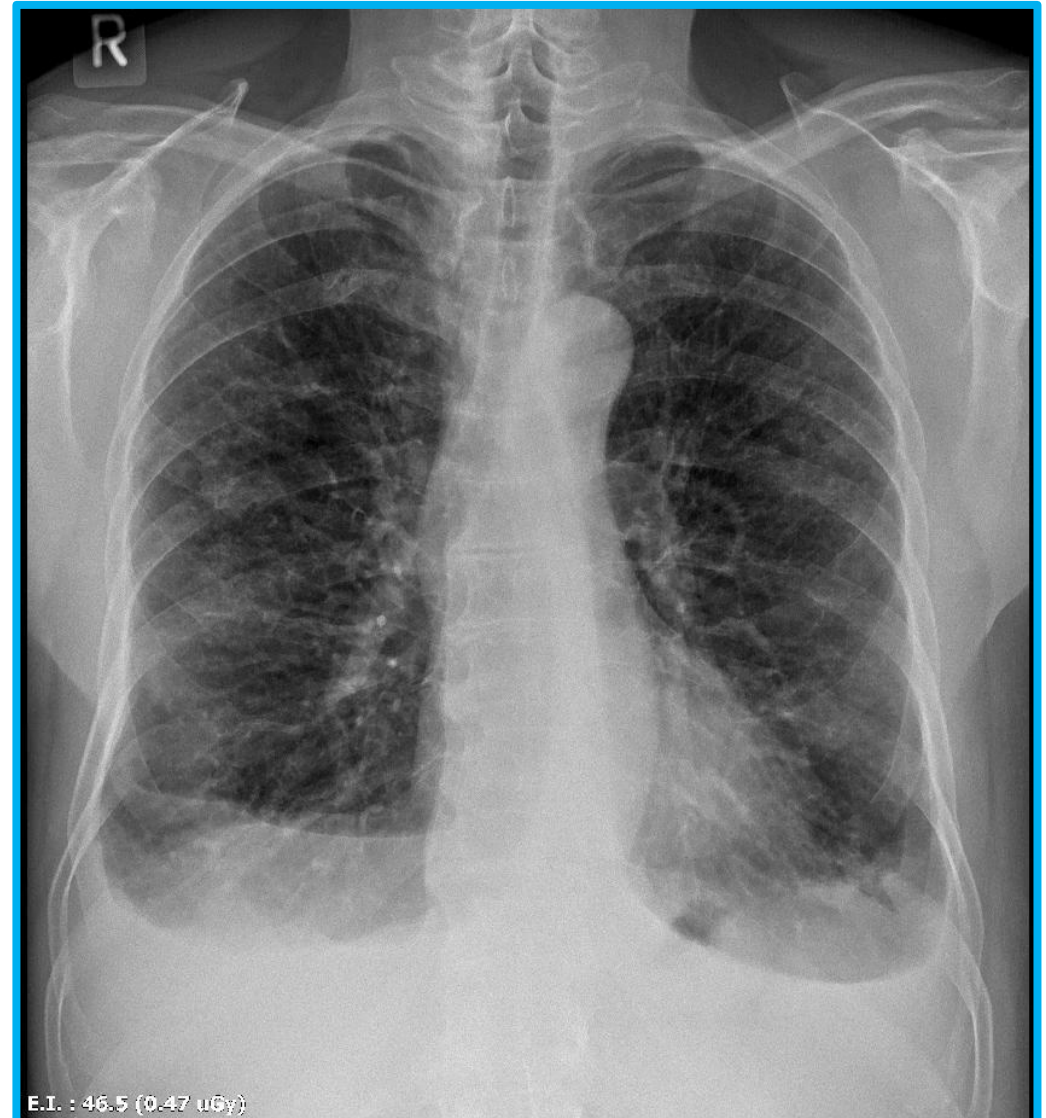
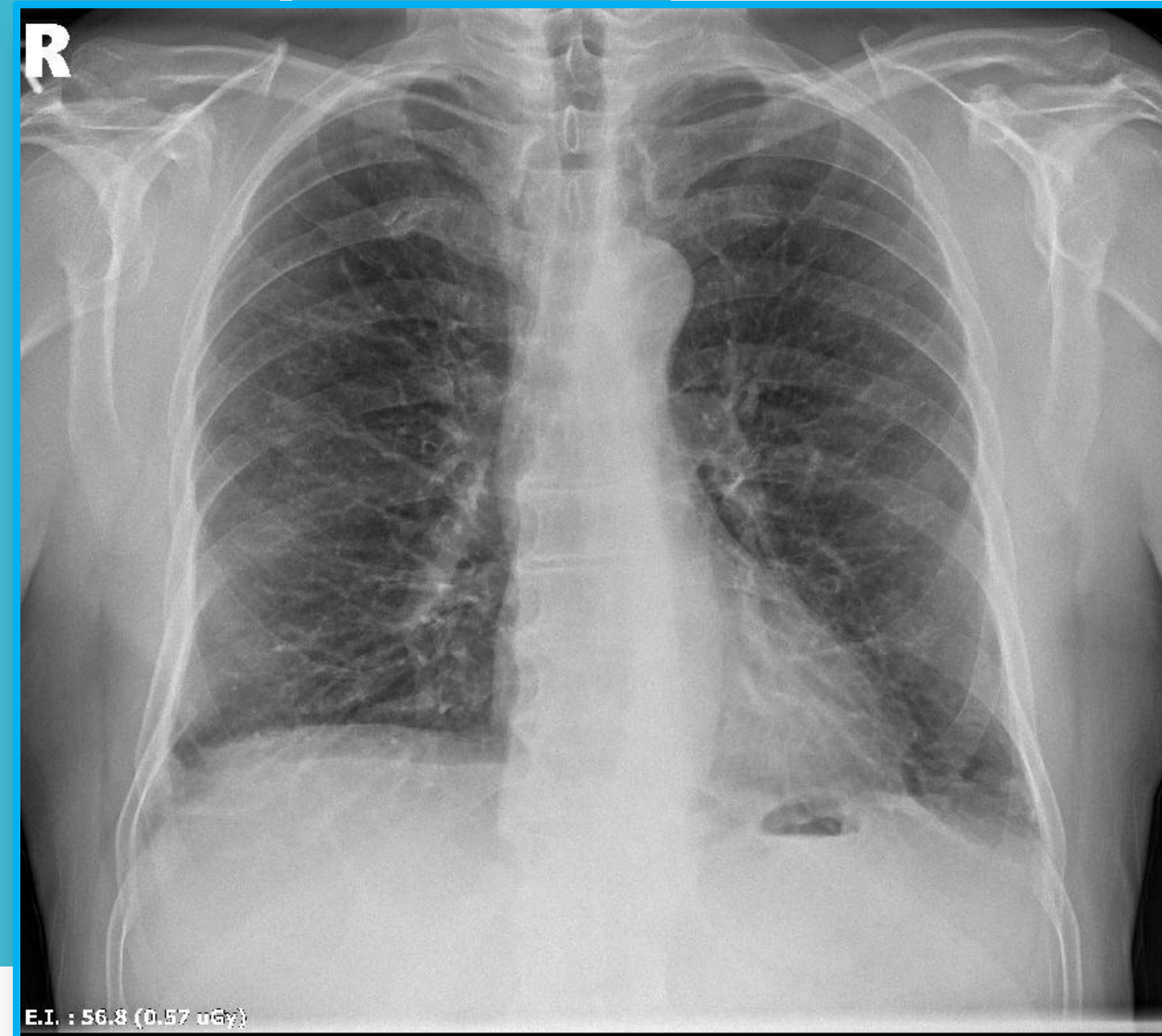
## PULMOLOG → INTERVENTNI PULMOLOG

- 
- BRSK sa TBB:
  - S. Aureus S na moksifloksacin
  - MTBC PCR/ DNA nije detektirana
  - BK negativan
  - Gljive NISU IZOLIRANE

**PHD TBB: HISTOLOŠKI NALAZ UKLAPA SE U SLIKU  
REUMATOIDNIH NODULA U PLUĆIMA**

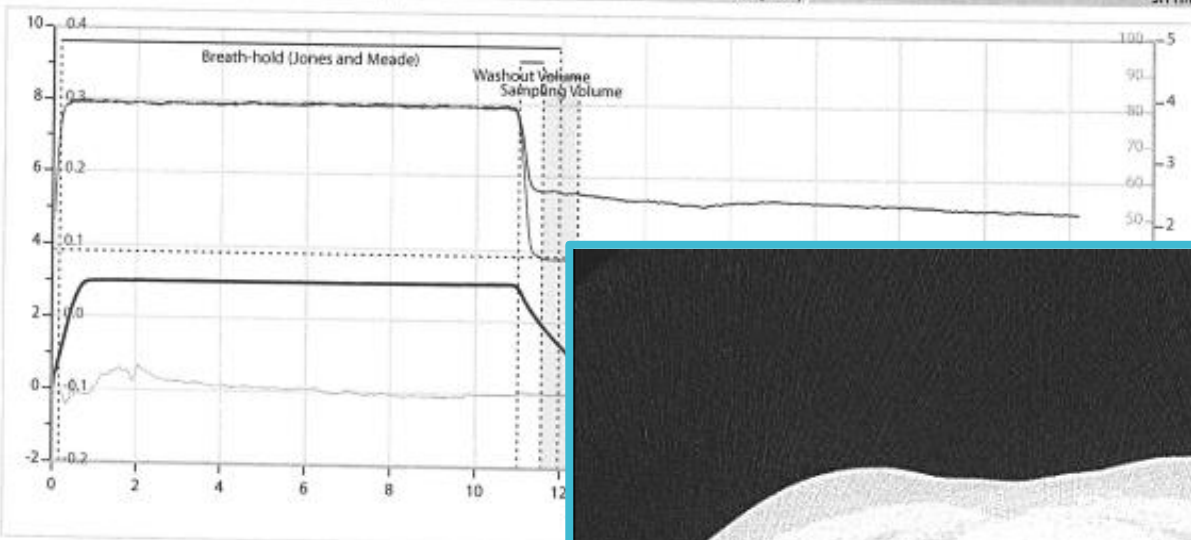


RTG → 2 tjedna



### DIFFUSING LUNG CAPACITY (SINGLE BREATH)

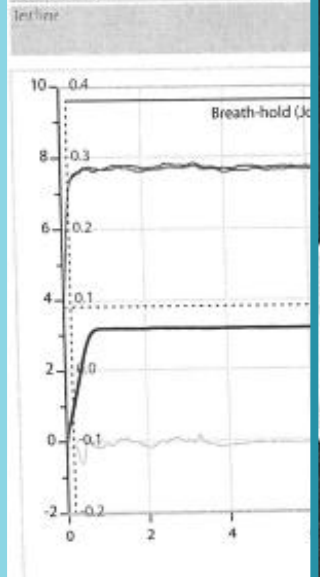
Figures	Device	Serial Number	Firmware Version
X9	Quark PFT with dongle	2023052156	4
Test Name	Set	Test Position	
11:06		GLI (DLCO)	SITTING



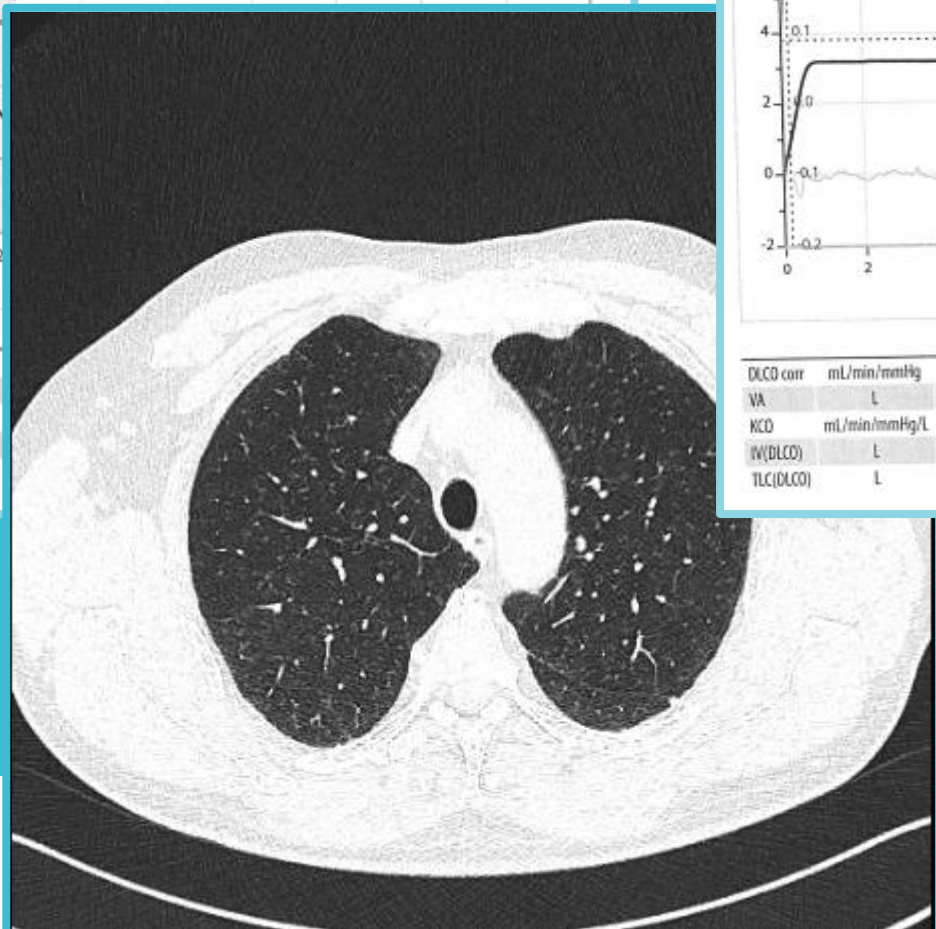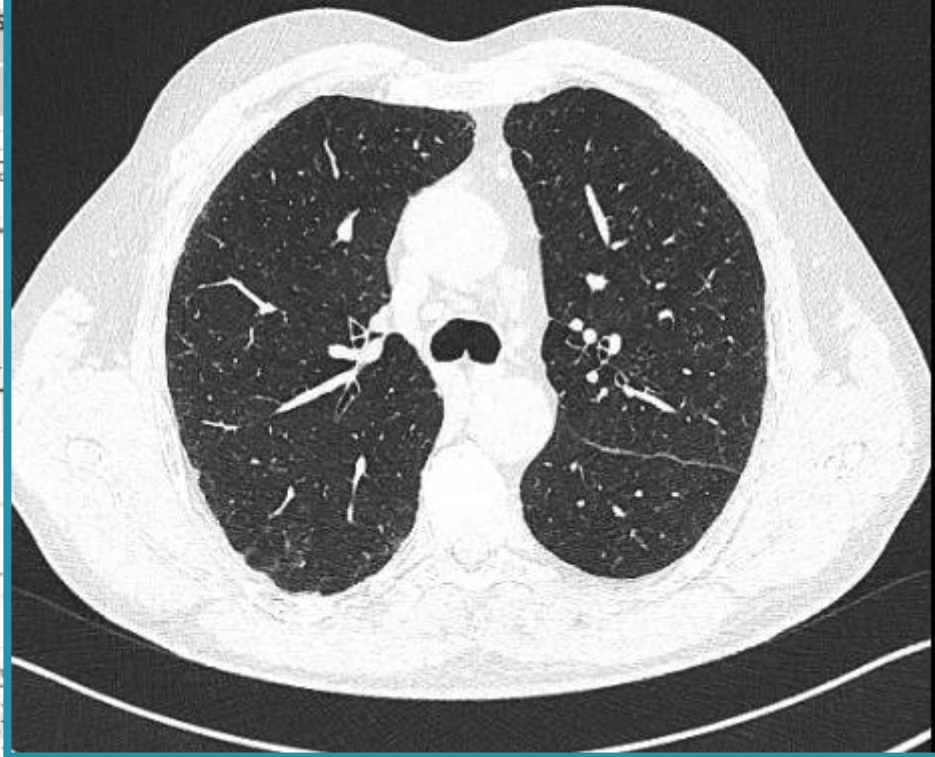
	Meas.	Pred	% Pred	z score
DLCO corr	18.57	25.68	72	-1.79
VA	4.43	6.16	72	-2.46
KCO	4.20	4.19	100	0.00
IV(DLCO)	3.01	4.65	65	-2.89
TLC(DLCO)	4.59	6.84	67	-2.70

→ 6  
est  
niti  
njen  
nja

### DIFFUSING LUNG CAPACITY (SINGLE BREATH)

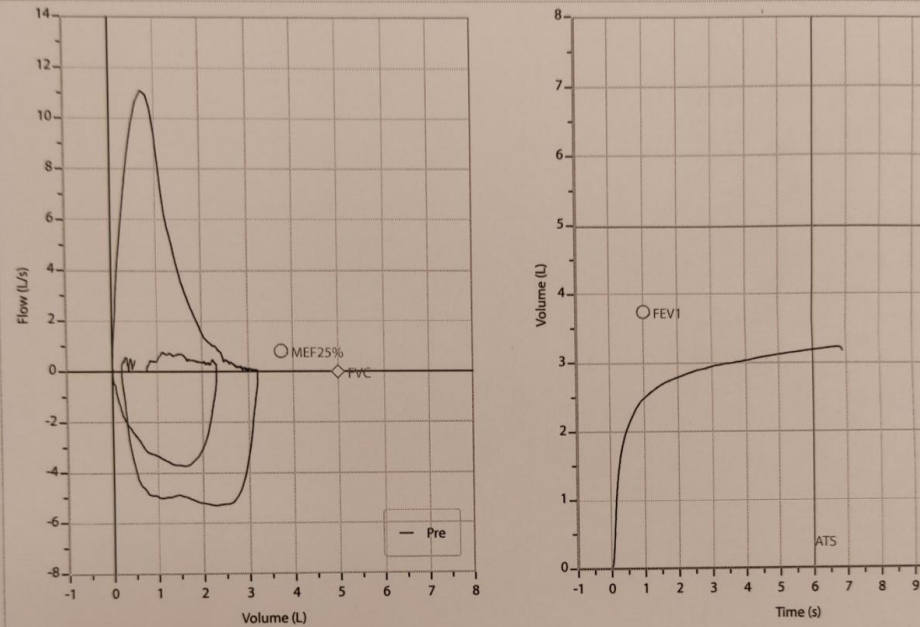


	Meas.	Pred	% Pred	z score
DLCO corr	17.12	25.68	67	-2.55
VA	4.43	6.16	72	-2.46
KCO	3.86	4.19	92	-1.10
IV(DLCO)	3.19	4.64	69	-2.55
TLC(DLCO)	4.59	6.84	67	-2.69



- U redovitim reumatološkim kontrolama
- U terapiji tocilizumabom
- Klinički stabilno
- Plućna funkcija za sada svaka 3 mjeseca

SCRIP  
JEVA

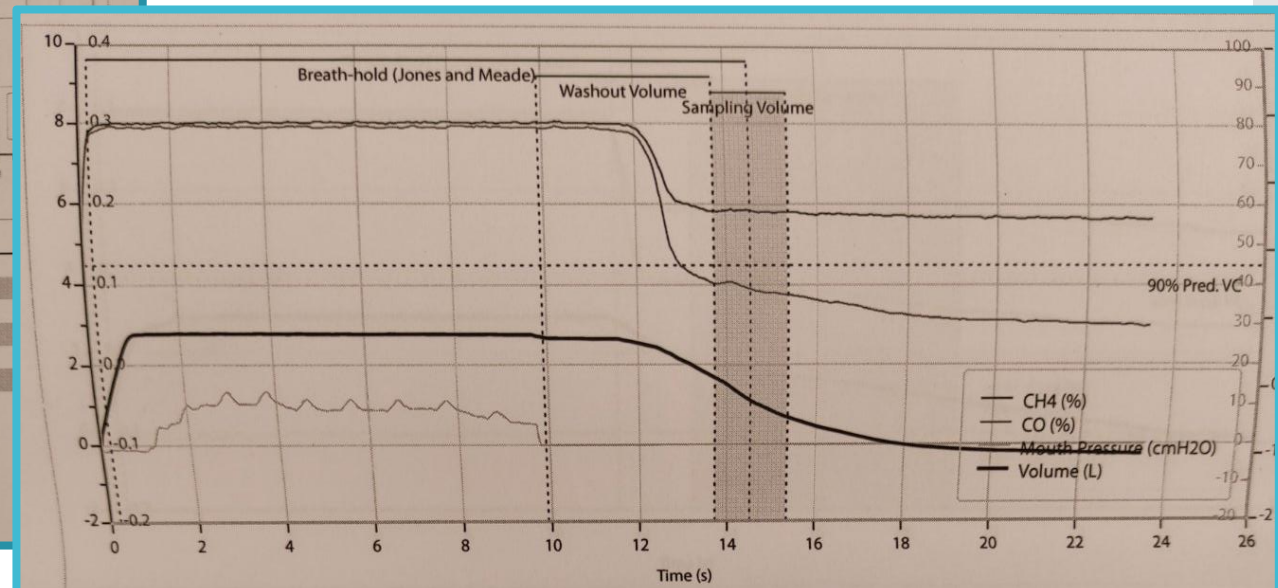


	Meas.	Pred	% Pred	z score	
FVC	L	3.22	4.98	65	-2.31
FEV1	L	2.53	3.75	67	-1.97
FEV1/FVC%	%	78.5	75.7	104	0.39
FEV1/VCmax%	%	78.5	75.7	104	0.39
FEF25-75%	L/s	2.23	2.83	79	-0.56
PEF	L/s	11.09	-	-	-
FVC	L	3.00	4.98	60	-2.60

FEV1 GRADE: A - EXCELLENT  
 FVC GRADE: A - EXCELLENT  
 OPERATOR QC PRE: -

HRCT : nalaz u prilog fibrozirajuće bolesti plućnog intersticija, koja se najviše uklapa u radiološku sliku fibrozirajućeg NSIPa

Odlukom konzilija započeto je liječenje biološkom terapijom.



	Meas.	Pred	% Pred	z score	
DLCO corr	mL/min/mmHg	12.34	29.42	42	-4.24
VA	L	3.76	7.40	51	-4.51
KCO	mL/min/mmHg/L	3.28	4.00	82	-1.14
IV(DLCO)	L	2.78	5.37	52	-3.99
TLC(DLCO)	L	3.96	8.16	48	-4.19

# Teamwork makes the dream work



Thalassotherapia  
Opatija

Specijalna bolnica za  
medicinsku rehabilitaciju  
bolesti srca, pluća i reumatizma